

**DATE**

4/8/22

PRESENTING CLINICAL SIGNS

History of intermittent vomiting since 2021. 4/6/22- 3lb weight loss since 1/6/22, intermittent vomiting with somewhat decreased appetite. Grade 2/6 murmur, HR >180, mild dehydration, non tender abdomen.

PATIENT

Roe Giuliano

Current Medications: Cerenia 16mg ½ EOD.

Date of Previous IntraPet Ultrasound: No previous.

Sedation: Not required to complete full diagnostic ultrasound.

Stat Report: Not requested.

Imaging Performed By: Rachel Brillhart, RDMS.

SPECIES

Feline

BREED

DSH

SEX

Neutered Male

AGE

8/1/11

WEIGHT

7 Pounds 4 oz

ULTRASONOGRAPHIC EXAMINATION OF THE ABDOMEN**Urinary System**

The **urinary bladder**, trigone, and pelvic urethra presented normal thicknesses and normal tone. The ureters were not visible which is normal. No uroliths or sediment were visualized and anechoic urine was present. No evidence of inflammatory or neoplastic changes were noted. Ureteral papillae were normal.

The **kidneys** revealed largely normal size and structure, corticomedullary definition and ratio (cortex 1/3 of medulla) were essentially maintained with some moderate age-related loss of curvilinear patterns regarding the capsule and C/M junction. The cortices presented largely uniform texture with some increased echogenicity expected for his age patient. Medullary structure differed distinctly from that of the cortex and no evidence of pelvic dilation was present. The right kidney measured 3.52 cm. The left kidney measured 3.86 cm.

Adrenal Glands

The regions of the **adrenal glands** revealed no evident pathology.

Spleen

The **spleen** in this patient was uniform, yet volume contracted. Hydration status should be assessed.

Liver

The **liver** revealed heterogeneous mixed hypoechoic nodular changes, mildly disruptive. Concern for metastatic disease. The gallbladder and common bile duct were unremarkable.

Gastrointestinal

The **stomach** revealed a significantly disruptive concentric mass, measuring approximately 5.3 cm x 4.2 cm, occupying the gastric fundus. A complete loss of structural detail was noted. Minor variable small intestinal thickening noted elsewhere without overt neoplastic criteria.

Pancreas

The base and limbs of the **pancreas** were observed to be largely isoechoic to surrounding omental fat. Some minor parenchymal remodeling, however, with mild deviation from curvilinear normalcy was observed. Pancreatic duct and capsular irregularities were present consistent with age related changes. If pain upon imaging (+ Murphy sign) was present or if the patient is focally painful in subxyphoid palpation then low-grade smoldering chronic pancreatitis should be suspected.

ULTRASONOGRAPHIC FINDINGS**INTERPRETED BY**

Eric Lindquist, DMV
DABVP, Cert. IVUSS

HOSPITAL NAME

Chadwell AH

REFERRING VET

Dr. Oliveri

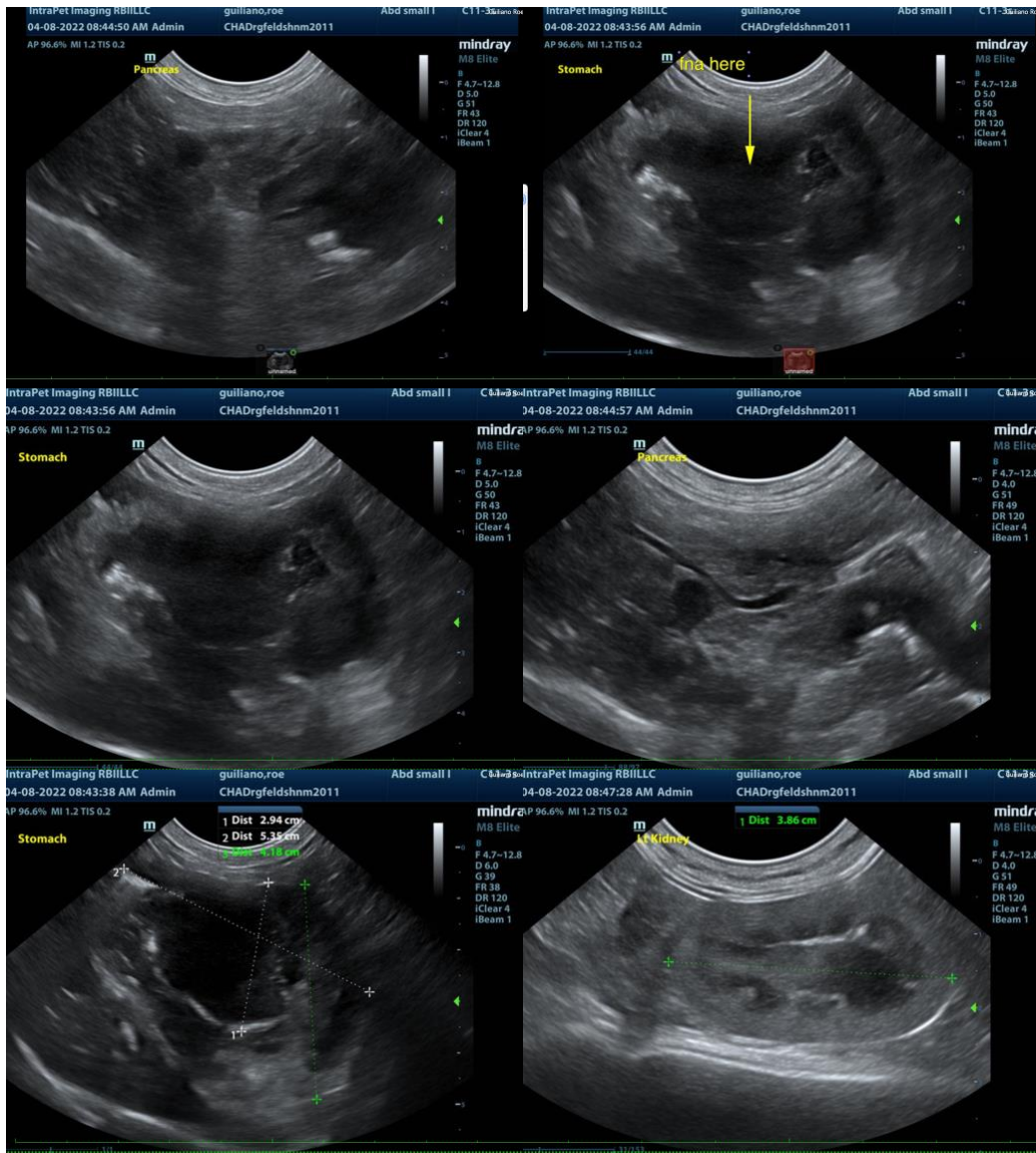
INVOICE

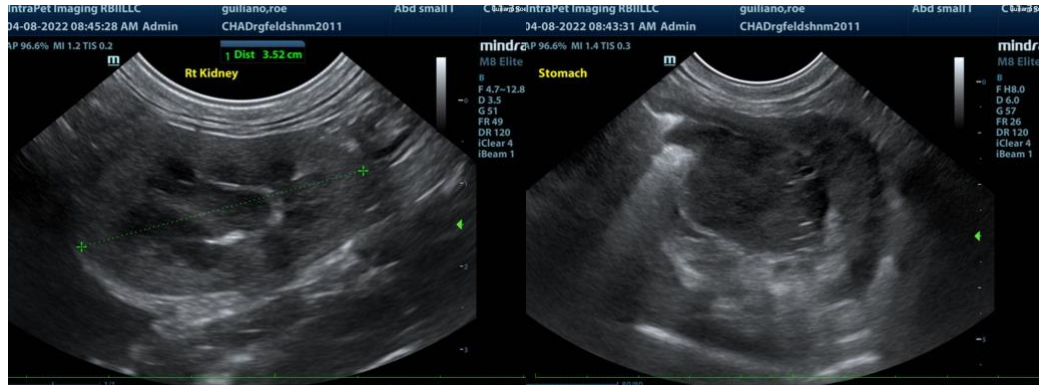
14677

- Gastric +/- hepatic neoplasia, round cell neoplasia pattern/lymphoma- FNA indicated
- Volume contracted spleen
- Age-related renal and pancreatic changes

INTERPRETATION OF THE FINDINGS & FURTHER RECOMMENDATIONS

Ultrasound guided FNA of the gastric mass warranted to confirm suspicion of lymphoma.





The information and recommendations provided are based on the images presented by the referring veterinarian. No evaluation can be communicated regarding pathology that was not visible in the image/video clips provided.

Thank you for this referral. If the clinical or image interpretation does not parallel your findings or if I can be of any further assistance please contact me.

Eric Lindquist, DMV, DABVP, Cert. IVUSS, CEO of SonoPath.com
Eric.Lindquist@SonoPath.com

Feline Lymphoma and Intestinal Neoplasia

<http://www.sonopath.com/FelineGILSA>
<http://www.sonopath.com/FelineGICarcinoma>

Description: The gastrointestinal (GI) tract is a common site for lymphoma in cats. In addition to the GI form, the most prevalent feline lymphomas are leukemic and mediastinal. Multicentric lymphoma occurs less frequently in cats than in dogs. Researchers have documented an association between FeLV and the development of lymphoma in cats; the incidence registers somewhere between 12-80%, depending on the location of the lymphoma. Typically, the leukemic and mediastinal forms tend to occur in young cats with concurrent FeLV positive titers, while GI lymphoma occurs more frequently in older patients that present as FeLV negative. Yet, recent studies using PCR have demonstrated that the incidence of FeLV positivity in cases of GI lymphoma can be as high as 63%, putting into question previously held beliefs about the etiological patterns of the disease.

Feline lymphoma in younger cats is typically of the intermediate to large cell variety. Older cats usually display small cell lymphoma, which is often difficult to differentiate from lymphocytic inflammatory disease or hyperplasia. B cell lymphoma often derives from the gut-associated lymphoid tissue (GALT) and is the most common type of alimentary lymphoma in cats. Renal lymphoma is typically the large cell type and nearly always occurs bilaterally. It may be confirmed by dual renal ultrasound-guided FNA, and is often localized in the kidneys. Renal lymphoma may be associated with the alimentary form and/or nasal

lymphoma. Hepatic lymphoma is also usually the large cell form and is the most common type of feline liver tumor; it is especially prevalent in older cats. Mediastinal lymphoma originates in the thymus and is found mostly in younger FeLV-positive cats.

Clinical Signs: Older, domestic shorthair cats tend to be those most commonly affected by GI lymphoma. Nondescript symptoms include weight loss, diarrhea, vomiting, and anorexia; lethargy may or may not be present. Bloodwork can often be unremarkable; however, hypoalbuminemia is the most prevalent finding (present in 50% of cases). A palpable abdominal mass is present in approximately one third of cases, while another third typically presents with thickened bowel loops. A modified transudate or chylous effusion ascites may develop due to lymphatic obstruction. If the lymphoma metastasizes from the thoracic duct into the thorax, then a similar effusion may occur within the thoracic cavity; the resultant respiratory signs and pleural effusion will be evident on radiographs. Over half of the cases present clinically with normal abdominal palpation. Radiographs are also often of little diagnostic relevance for this disease until a visible mass or obstructive pattern develops.

Diagnostics: Ultrasound diagnostics make early detection quite reliable, and the reliability increases when the GI tract has been properly prepared (this requires the patient to have fasted for 12 hours prior to the ultrasound). Fine needle aspirates or guided biopsies may be obtained in order to stage and differentiate this disease from chronic inflammatory disorders (i.e., inflammatory bowel disease [IBD]) or other neoplasia (i.e., adenocarcinoma, mast cell tumor). Endoscopy is also quite dependable; however, vague changes may or may not be noted in the mucosa. These lesions include irregular mucosae, pallor, friability, erosions, and ulcers. Occasionally, a discrete mass may be seen, but usually a mucosal biopsy is necessary for differentiation.

There are different grades of GI lymphoma: i) low grade alimentary lymphoma (LGAL); ii) poorly differentiated (lymphoblastic or high grade alimentary lymphoma [HGAL]); and iii) intermediate grade alimentary lymphoma (IGAL). Tumor locations tend to differ according to the grade of lymphoma present. Ninety percent of lymphocytic lymphoma involves the small intestine only, while the remaining cases involve the small intestine as well as gastric tissue. Lymphoblastic lymphoma cases that affect the small intestine exclusively occur 50% of the time, while one-third of cases involves the stomach exclusively; the remaining cases affect both organs. In one study of 67 cases, 75% were defined as lymphocytic and 25% as lymphoblastic upon histological examination. In fact, cytological diagnoses are achieved more frequently when assessing HGAL and IGAL; however, histology is often required to diagnose LGAL. Palpable abdominal masses are noted much more frequently in cases of HGAL and IGAL than in those of LGAL. Ultrasonography may show GI mural masses, diminished wall layering, or wall thickening. Anemia is more characteristic of HGAL and IGAL than LGAL.

Ultrasound-guided sampling is readily obtainable on most suspected organs (e.g. liver, spleen, kidney, pancreas, lymph nodes) and masses, but surgery may be indicated when a patient presents with diffusely thickened bowels and one must differentiate IBD from intestinal LSA. Although fine needle aspiration (FNA) is usually adequate for obtaining a cytological diagnosis, it can sometimes present a challenge when one is distinguishing between small cell lymphoma and hyperplasia; however, special staining, such as PARR, or the use of PCR can help clarify the difference. These tests also help differentiate monoclonal from polyclonal lymphoma, which can help practitioners refine their therapeutic protocols

and prognoses. In cases where these tests do not provide sufficient information, core or surgical biopsy is necessary for differentiation.

The crypt of Lieberkühn (intestinal gland) is also vulnerable to adenocarcinoma, which accounts for 25-30% of all GI neoplasms. Luminal stricture occurs in approximately 25% of those affected. It typically affects cats between the ages of 8 and 11; the Siamese breed represents 71% of all cases. Seventy percent of cases occur in the small intestine (primarily the duodenum) and the remainder in the colon. Metastatic spread via the lymphatic system to the mesenteric lymph nodes occurs 50% of the time and carcinomatosis occurs 29% of the time; the lungs and liver are often affected. Surgical resection and anastomosis are the treatments of choice for adenocarcinoma and should be followed by chemotherapy with doxorubicin every 3 weeks for a total of 5-6 treatments. Prognosis varies, depending upon the study. In one study, a 10-month median life span was observed if metastasis was present at diagnosis (range 0-28 months). Characterization of the adenocarcinoma will dictate the prognosis: those with the tubular form have a longer median survival time (MST) of 11 months compared to patients with the undifferentiated and mucinous types (4 months).

Ultrasound and endoscopy can offer early detection of GI lymphoma and help to differentiate it from other diseases with similarly vague signs (i.e., IBD, pancreatitis, hepatic lipidosis, triaditis, and other neoplasia). These techniques also allow one to determine if surgical intervention is necessary (i.e., as opposed to medical therapy for IBD or chemotherapy for diffuse lymphoma). For instance, cases of adenocarcinoma and lymphoblastic lymphoma tend to obstruct the intestinal lumen more readily than lymphocytic lymphoma and would therefore require surgical bowel resection. Definition and staging of the disease is facilitated noninvasively through biopsy procedures. These enable the practitioner to determine the course of treatment, ascertain a prognosis, and arrive at a rapid conclusion. Moreover, a sampling of the liver—the most frequent site of metastatic spread—may be performed simultaneously to assess further the extent of the pathology.

Treatment: Small cell lymphocytic lymphoma is typically treated with oral chemotherapy, which includes administering prednisone (1-2 mg/kg PO Q24hr, then 1 mg/kg Q48hr) and chlorambucil (20mg/m² PO Q14 days). Alternative protocols also exist: prednisone can be given at 10 mg/cat/day and chlorambucil at 15 mg/m² once a day for 3 days and repeated at three-week intervals. Different studies have demonstrated the success of these protocols, which are well tolerated and have resulted in remission rates of 69% with an MST of 20.5 months (range 5.8-49 months). Rare adverse side effects to the chemotherapy include gastrointestinal signs, anorexia, and leukopenia. Remission is usually achieved within 3 weeks and may be assessed and quantified by ultrasound examination. In the case of recurrence, rescue chemotherapy can be implemented with cyclophosphamide.

A more aggressive approach is recommended for cats with lymphoblastic lymphoma; it entails using combination chemotherapy, such as cyclophosphamide, vincristine, and prednisone, with or without doxorubicin. Yet, remission rates are much lower for patients with lymphoblastic lymphoma than those with small cell lymphoma. In one study, the MST was reported to be 2.7 months for lymphoblastic cases. The presence of abdominal masses is more common with lymphoblastic lymphoma, and patients with this type of cancer may therefore also require surgical resection. Consultation with an oncologist is strongly advised.

References:

Barrs V, Beatty J. Feline alimentary lymphoma: 2. Further diagnostics, therapy and prognosis. *J Feline Med Surg* 2012;14(3):191-201.

Fondacaro J, Richter K, Carpenter J, et al. [Feline gastrointestinal lymphoma: 67 cases \(1988-1996\)](#). *Eur J Comp Gastroenterol* 1999;4(2):5-11.

Russel KJ, Beatty JA, Dhand N, et al. Feline low-grade alimentary lymphoma: how common is it? *J Feline Med Surg* 2012;14(12):910-12.

Stein TJ, Pellin M, Steinberg H, and Chun R. Treatment of feline gastrointestinal small-cell lymphoma with chlorambucil and glucocorticoids. *J Am Anim Hosp Assoc* 2010;46(6):413-17.

Twomey LN, Alleman AR. Cytological diagnosis of feline lymphoma. *Comp Cont Educ Pract Vet* 2005;27:17-31.

Wilson H. Feline alimentary lymphoma: demystifying the enigma. *Top Companion Anim Med* 2008;23(4):177-84.